

Diagnosing and Treating the Patient with Restricted Mandibular Opening: A New Approach

CE 2

Abstract: *Patients with a restricted mandibular opening and related pain require a systematic process for differential diagnosis and treatment planning. This article considers the differential diagnostic process, treatment planning, and treatment delivery for a patient seeking a second opinion before surgery for a closed lock. A closed lock occurs when the disc in the joint has been pulled off the head of the condyle and forward, blocking the condyle from translating forward.*

Jerry Simon, DDS, FAGD
Private Practice
New York, New York

Learning Objectives:

After reading this article, the reader should be able to:

- identify the cause of restricted mandibular opening.
- describe how to capture a centered bite record.
- explain the laws of healthy functional occlusion.

One of the more challenging situations that dentists encounter is diagnosing and treating patients with restricted mandibular openings. These patients generally present with both a physical and emotional problem.¹ They are frequently in pain, upset, fearful, and under considerable stress. The dentist's responsibility is to confirm a diagnosis and determine how to provide temporary relief as well as to create a long-term treatment plan.

Consider the differential diagnosis:

- Trismus from infection related to a wisdom tooth²
- Trauma from a fractured jaw³
- Muscle spasm as a result of occlusal interference⁴
- Closed lock (the disc has been trapped in front of the condyle, preventing translation and mandibular opening) (M.A. Piper, MD, DMD, unpublished lecture material)
- Tumor in the temporomandibular joint (TMJ)
- Infection in the TMJ

The patient history is essential. The dentist should ask the following questions when attempting to diagnose a patient:

- Has the problem occurred before? Has there been previous treatment? If so, what treatment was rendered and what was the outcome?
- Does the patient have wisdom teeth?
- Is there a history of problems with wisdom teeth?
- Has the patient had any recent head, neck, or facial trauma?
- Is there a history of whiplash (such as a motor vehicle accident)?
- Does the patient have a history of joint problems?
- Has the patient experienced previous incidents of limited opening?
- Is there a history of joint sounds, such as clicking on opening and closing, that would indicate that the disc has been displaced but is being recaptured in translation?
- If there is a history of clicking of the jaw joint, has the sound stopped recently, indicating that the disc is no longer being recaptured?
- Does the patient currently have pain? How long has the pain been present?

- Do the pain and limited opening occur simultaneously?

If the history rules out trauma, and a panoramic x-ray indicates that the involvement of the third molars is unlikely, the dentist can begin to consider the potential of TMJ issues, such as muscle spasms and/or disc displacement.

The traditional clinical method of eliminating muscle spasms has been the “spray and stretch” technique.⁵ The clinician applies a spray of ethyl chloride or a similar agent to the patient’s face to attempt to break the muscle spasms while the patient opens and closes his or her mouth. A rapid and significant increase in opening has been used to indicate muscle spasm as the cause of the limited opening, as opposed to another cause, such as a locked disc.

While the spray and stretch method often helps, it also has 2 important limitations. First, the ethyl chloride is being applied to the outside of the face, so a thick mass of tissue must first be penetrated to affect the muscles. Second, the duration of the “cold” is fairly brief, limiting the dentist’s ability to determine the status of the disc. Plus, if the spray and stretch is effective, the clinician does not have an immediate way to help the patient avoid reoccurrence of the spasm (M.A. Piper, MD, DMD, unpublished lecture material).

Another technique that has been advocated to treat closed lock is injection of a short-acting anesthetic (such as 3% lidocaine) without vasoconstrictor in the superior compartment of the joint space.

The mechanism of such a procedure is subject to debate; in the author’s opinion, the local anesthetic breaks muscle spasms that are holding the jaw closed. The approach is to insert a 27 or 30 gauge needle extraorally directly over the TMJ. The patient is instructed to open and close as far as possible while the practitioner palpates the head of the condyle. The penetration and injection is accomplished slowly as the needle advances.⁶ Aspiration is essential to be sure that the needle does not inject into the vascular tissues.

The procedure sometimes works in just a few minutes and allows considerable increase in range of motion. If it does not work, the patient is dismissed with instructions to apply hot and cold packs to the area and gently attempt to open, and to contact the practitioner either as

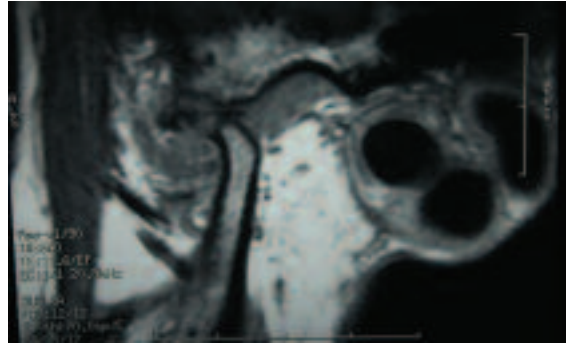


Figure 1—Severely displaced disc without limited range of motion.

soon as range of motion has increased or 2 days, whichever comes first. In the author’s opinion, if this methodology does work, the reason is that the local anesthetic has interrupted a muscle spasm in the TMJ complex.

The only way to be certain of the position of the disc is through magnetic resonance imaging (MRI).⁷ With MRI, the location of the disc is visible in 3 dimensions and from the lateral pole to the medial pole of the condyle. This is essential because the disc may be displaced on only the lateral pole, or on both the lateral and medial poles. In addition, the direction of displacement may be toward either the medial or lateral poles.

While MRI is the gold standard in TMJ disc evaluation, the time, expense, and limited availability to obtain this imaging can present at least a temporary barrier to the dentist. In addition, scheduling and getting the results of the MRI scan in less than a life-threatening situation will likely take several days, which can be frustrating to the patient as well as the practitioner. Also, once the position of the disc is determined, it still may not give the practitioner the information that is needed to stop the pain and regain normal range of motion. It also is important to note that the location of the disc does not always relate to the amount of mandibular opening.⁸ Figure 1 shows the MRI of a different patient who had a displaced and nonrecapturing disc. It is interesting to note that during examination, despite the fact that the disc was severely displaced both from the medial and lateral poles of the condyle, there was absolutely no restriction of mandibular movement, with maximum opening at 49 mm.⁹

Case Study

A 32-year-old woman presented to the author’s office with acute myofascial pain and

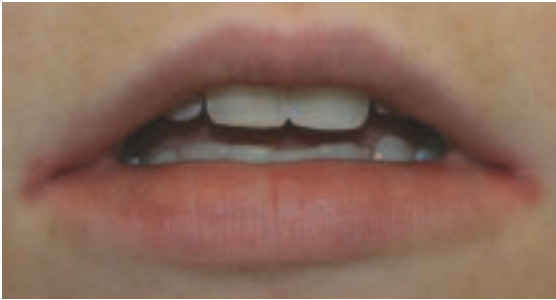

Figure 2—Opening limited to 6 mm.

restricted mandibular opening. She had suffered 3 weeks with severe pain and limited opening. Further questioning and a patient intake form revealed that she had suffered with chronic head, neck, and facial pain since high school. Her medication history indicated extended and unsupervised use of a nonsteroidal antiinflammatory drug. She reported taking Advil and Aleve several times a week for many years. Recently they had become less effective, resulting in an increase in dosage and frequency. She had been given prescriptions for cyclobenzaprine hydrochloride as a muscle relaxant, diazepam as a tranquilizer, and oxycodone HCl as a pain reliever. However, this combination was providing limited relief and the patient was growing concerned with the drug regimen, especially because there was no defined end point.

The patient's general dentist referred her to a second dentist with more experience with TMJ dysfunction, who performed a spray and stretch procedure that did not relieve the acute pain or increase her opening. As a result she was referred to an oral surgeon for further evaluation. The oral surgeon was in the process of scheduling joint surgery, although the patient was not clear at the time of the visit to the author's office as to the specific nature of the proposed procedure.

The patient arrived at the office unable to open her teeth more than 6 mm from upper to lower incisal edges (Figure 2). In addition, she rated her acute pain on the visual analogue scale (VAS) as 6 of 10. She was frightened by the idea of jaw surgery and visibly stressed.

There was significant pain during palpation of the jaw structures and muscles of mastication, indicting a potential TMJ disorder.¹⁰ In addition, occlusal examination revealed first contact on the right side and then the teeth had to shift forward and to the right for maximal intercuspation. Because of the muscle

spasms and restricted mandibular opening this occlusal relationship was noted, but was not considered to be definitive. The jaw joints were clearly destabilized by the unbalanced occlusion at maximal intercuspal position of the teeth, so the muscles were forced to stabilize the jaw joint.¹¹ Because this occurs 3,000+ times a day when a person swallows and chews food, it can overwork the muscles, causing spasms¹¹ and pain both in the muscles and the jaw structures that can radiate and refer to different parts of the head, neck, and face.

Because the author did not know the cause of the pain and limitation in range of motion, it was decided to attempt to deprogram the muscles. The objective was to determine if the limited opening was the result of muscle spasms as opposed to a displaced disc or other anatomic aberration that was blocking mandibular translation.¹²

The challenge is that the muscles will not relax until the condyles are centered, but the condyles cannot center if the muscles will not relax to their full resting length.¹³ This conundrum becomes a barrier to correct diagnosis and treatment. In addition, attempting to forcibly push the mandible to a more centered position is likely to induce a reflexive push back that will defeat the purpose of centering the condyles. For this reason, the author elected to use a device to assist in the process.

There is a long history of assisted deprogramming in the dental literature, from the leaf gauge¹⁴ first described in the 1930s, to custom deprogrammers as described by Neff¹⁵ and Dawson,¹⁶ the Aqualizer^a, Lucia Jig^b, the Kois laboratory fabricated deprogrammer, and the ubiquitous doctor's tongue blade to the Best-Bite Discluder^c invented by the author.

The discluder is a prefabricated, "one size fits all" device that is customized chairside. With the 8 degree incisal table of the device acting as a fulcrum and guide and the muscles acting as the force, the discluder simultaneously prohibits occlusal interference and assists the condyles to seat up into a centered position, which allows the muscles to relax.¹⁷ If the limited opening and pain is caused by muscle spasms, this will relax the muscles and allow increased

^aJamar Industries, www.aqualizer.com; (800) 435-7863

^bPankey Institute, Key Biscayne, FL 33149; (800) 4-PANKEY

^cBest-Bite, www.Best-Bite.com; (888) THJ-SEEK

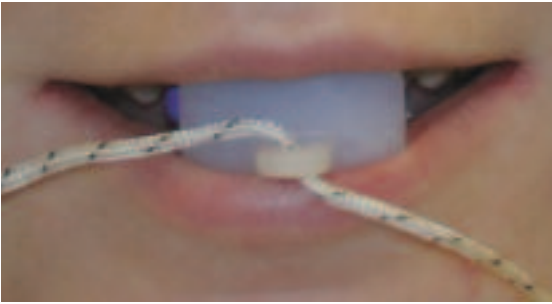
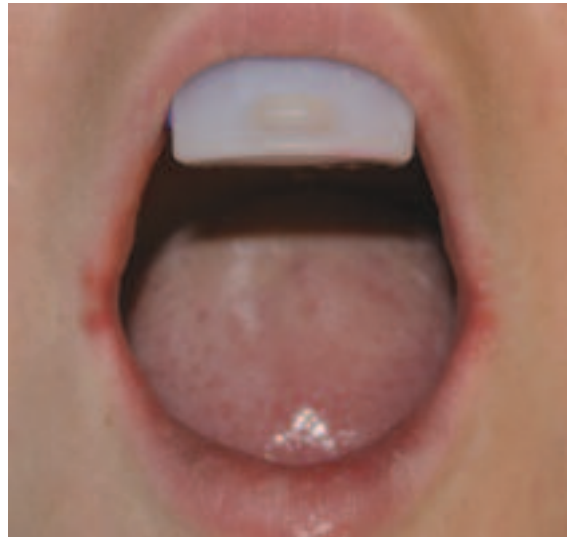
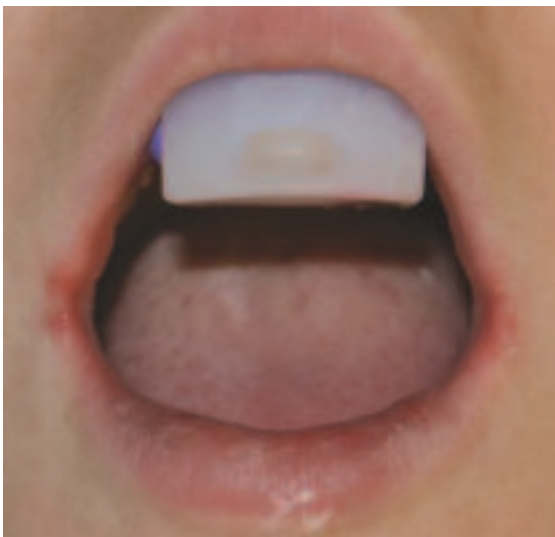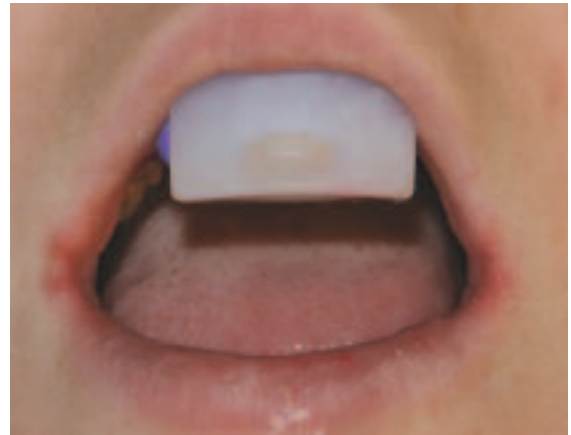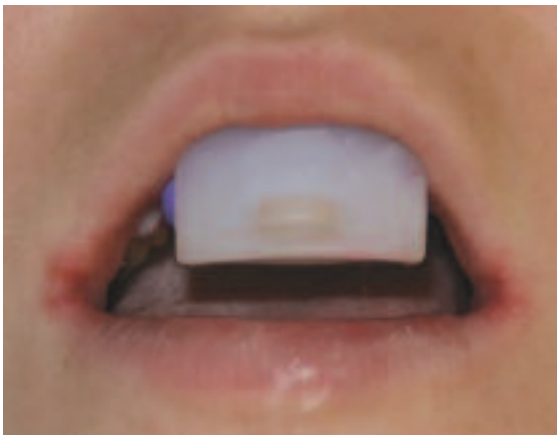Figure 3—Best-Bite fitted to patient with polyvinylsiloxane.

opening quickly as well as relieve acute pain.⁴ If the problem is related to the disc, there would be no significant change in range of motion. Figure 3 shows the Best-Bite device relined with impression material being fitted to the patient despite the limited opening. The patient was instructed to gently tap her teeth against the device to the best of her ability. The author occasionally assisted her in gentle tapping. Figures 4 through 7 are sequential photographs

that were taken over a period of 14 minutes. By the end of this period, the patient had improved to 39 mm of inter-incisal opening, and the acute pain was reduced on the VAS scale to 0. This demonstrated that the limited opening was in fact the result of muscles rather than disc derangement. Though disc derangement was present as well, it was not the cause of the restricted mandibular opening, and invasive procedures were contraindicated. The final diagnosis was occlusal muscle pain and limited range of opening caused by muscle spasms, secondary to a conflict between the teeth and the jaw joints. In addition to the immediate relief, the patient's experience with the discluder demonstrated that occlusal treatment (bite splint, equilibration, or restorative care) would provide long-term drug-free treatment.

At this point the patient's muscles were relaxed and her condyles were able to center. A surface electromyography (sEMG) verifies the



Figures 4 through 7—Photograph taken approximately every 3 minutes during 14 minutes of deprogramming.

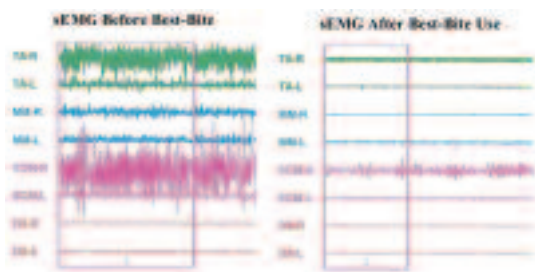


Figure 8—sEMG surface electromyograph before and after deprogramming surface.

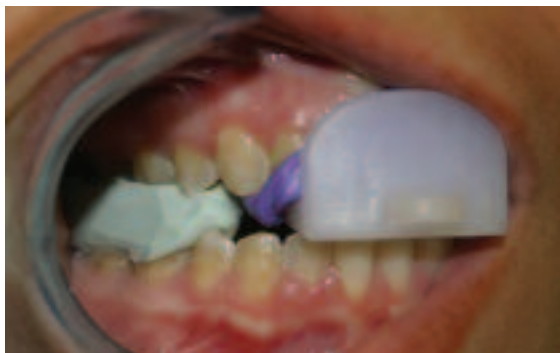

Figure 9—Bite record is captured.

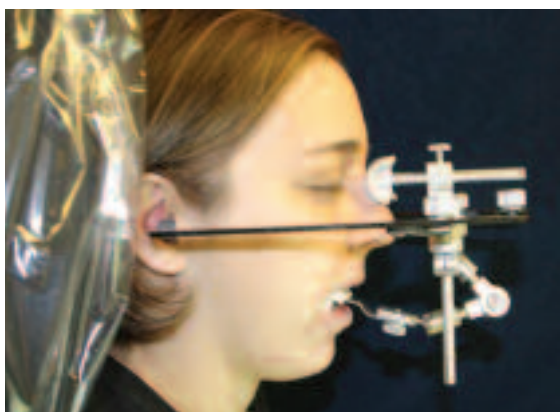

Figure 10—Facebow is recorded.

muscle activity before and after 5 minutes of deprogramming with the discluder (Figure 8). To verify that the joints were centered and there was no longer any muscle bracing, the jaw joints were loaded by pushing up at the angle of the mandible, using a technique described by Dawson,¹⁸ with no pain. This indicated that the joints were centered and free of muscle splinting.¹⁸ A bite record was taken in that unbraced position, and alginate impressions were taken. A facebow was captured with the Whipmix 9185 Facebow^d (Figure 9) and the study models were mounted on the Whipmix 4600 Arti-

^dWhip Mix Corporation, Louisville, KY 40217; (800) 626-5651

culator^d (Figure 10) to determine the best technique to create a coincidence of the patient's centered jaw position and their maximum intercuspated occlusion. The patient was given the Best-Bite Discluder to use at home as a short-term rescue device if the pain returned or if there was any hint of the muscles going back into spasm while a treatment plan was developed and the next visit was scheduled.

The patient was instructed to use the device for temporary relief of any pain or at the first sign of muscle cramping during the day with gentle tapping until the pain completely went away plus 1 more minute to be sure that the muscle spasm was fully relieved. In addition, the patient was instructed to use the discluder with gentle tapping for 10 minutes before bed as well as for 10 minutes on awakening for muscle release.

A trial equilibration on the mounted models indicated that an ideal result could be accomplished while removing an acceptable amount of tooth structure. The objective was to create a coincidence of centered condyles with full intercuspation of the teeth, as well as anterior and canine guidance.¹⁹ Because true centric relation requires the discs to be normal (and this patient does not and never will have normal discs), the patient was actually in adapted centric posture²⁰ as defined by Dawson to indicate that the condyles are in a centered position and unbraced by muscles with full intercuspation of the teeth.

This procedure of equilibrating the patient's teeth does 3 important things:

1. It optimizes the forces on the teeth and supporting structures so that the potential for dental damage is minimized. It directs the vertical closing forces generated by the jaw muscles down the long axis of the posterior teeth as much as possible. This is critical because the posterior teeth are closest to the jaw joints (fulcrum) and therefore subject to the heaviest loads. At the same time, it directs the nonaxial forces when the person bites side to side as far as possible from the fulcrum where the forces are weakest (anterior and canine guidance).
2. The procedure reduces muscle activity and thereby the forces on the jaw joints to reduce pressures on the joints and disc to minimize damage going forward.²¹




Figure 11—Case mounted on articulator with Best-Bite and posterior bite records.

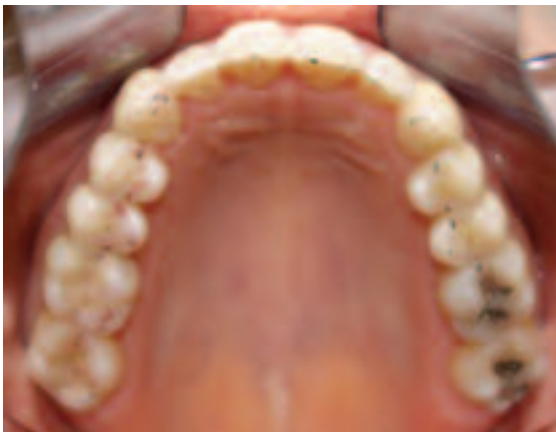

Figure 13—Occlusal contacts after equilibration.

3. By reducing muscle activity, the procedure reduces pain that is caused by or stimulated by muscles.¹⁷

The patient was treated over 4 visits by deprogramming the muscles and centering the jaw joints with the discluding device. First the patient's muscles were deprogrammed to allow the jaw joints to center in the fossa. Then the patient bit on Madam Butterfly[®] marking ribbon to create contact marks with the joints in the critical centered position. Any marks that identify premature and nonaxial loading on the posterior teeth were removed and then the remaining marks that were on cusp tips and fossa or marginal ridges were fine-tuned to create equal and simultaneous pressure on as many of the posterior teeth as possible.

[®]Almore International, Inc, Portland, OR 97296; (800) 547-1511

[®]Midwest Dental Equipment and Supply, Wichita Falls, TX 76701; (800) 766-2025

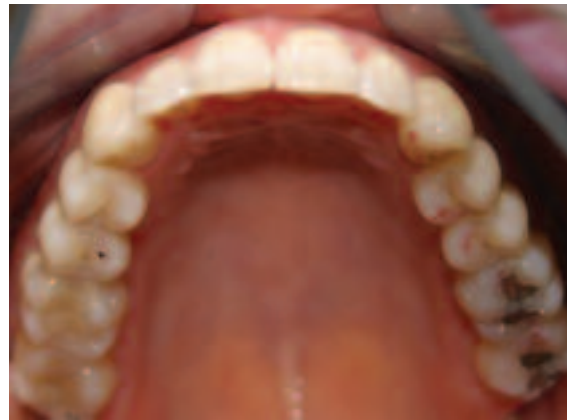

Figure 12—Occlusal contacts before equilibration.

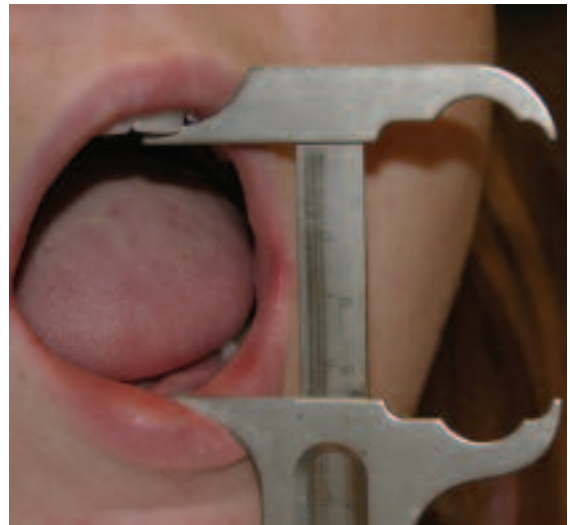

Figure 14—Full range of motion restored.

After 2 or 3 recordings with the marking ribbon, the jaw sliding is likely to reengage the muscles, so the discluding device is used again for 30 seconds to re-center the jaws and relax the muscles to ensure that adjustments are being made in the centered jaw position. For this case, Midwest[®] 1157 rounded end carbide burs were used for the equilibration process. Several visits are allocated for this process because the teeth will rebound after adjustments to equalize pressures, the muscles will adapt to the new occlusal relationships, and the process of adjusting the bite is fatiguing for the patient (Figures 11 through 13).

At the time of her fourth visit, the patient presented an MRI study of the TMJs (Figures 14 and 15). These images clearly demonstrate that there is a lateral pole disc displacement that was recaptured in translation (Figure 16), but the deprogramming conclusively proved that the displaced disc was not the cause of the restricted range of motion. That is why it is so critical

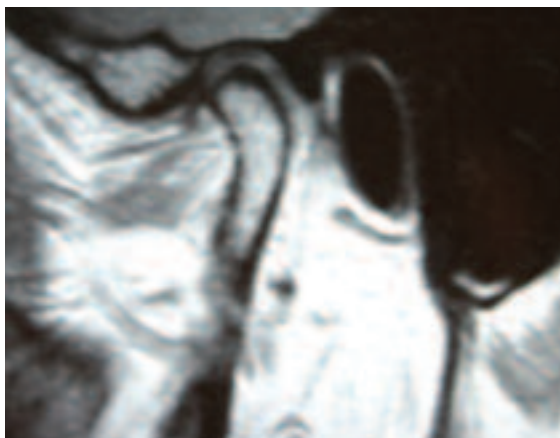


Figure 15—Jaw closed, disc displaced.

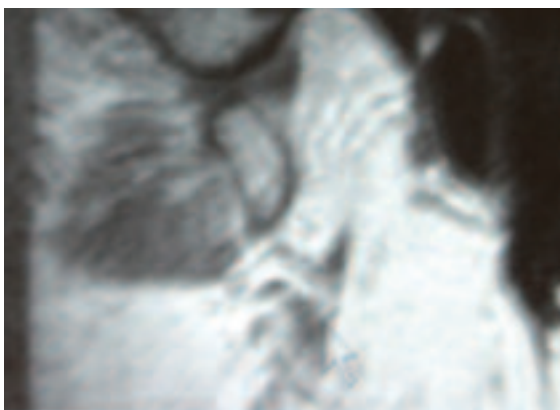


Figure 16—Jaw open, disc recaptured.

to not confuse “cause” (that the displaced disc was the cause of the restricted mandibular movement) and “condition” (that there was a simultaneously displaced disc, that will in fact never be recaptured, and a muscle spasm that caused pain and limited range of motion).

Conclusion

This case highlights several important points. First and foremost, long-term use of non-steroidal anti-inflammatory medications is neither always effective nor safe to manage pain. Second, a complete diagnosis must always be made before treatment is rendered. Surgery for this patient would not have in any way addressed the muscle spasm long-term, and the surgical trauma might well have made the situation much worse. Third, muscle spasm should always be suspected as a contributor to restricted range of motion of the jaw joints, as well as head, neck, and facial pain, and the simple and well-documented process of deprogramming should always be tried before more invasive procedures are attempted. Finally, displaced joints do not always

cause restricted movements and pain²² and conversely restricted movements are not always an indication of joint damage and disc displacement.

References

1. Yap AU, Chua EK, Hoe JK. Clinical TMD, pain-related disability and psychological status of TMD patients. *J Oral Rehabil.* 2002;29:374-380.
2. Ogi N, Nagao T, Toyama M, et al. Chronic dental infections mimicking temporomandibular disorders. *Aust Dent J.* 2002;47:63-65.
3. Goddard G. Articular disk displacement of TMJ due to trauma. *Cranio.* 1993;11:221-223.
4. Yamaguchi T, Satoh K, Komatsu K, et al. Electromyographic activity of the jaw-closing muscles during jaw opening—comparison of cases of masseter muscle contracture and TMJ closed lock. *J Oral Rehabil.* 2002;29:1063-1068.
5. Travell J, et al. *Myofascial Pain and Dysfunction: The Trigger Point Manual, Vol. 2: The Upper Half of Body.* 2nd ed. Lippincott Williams & Wilkins;1998:1218-129.
6. Spencer JR. Unlocking the on-reducing disc. *J American Academy of Craniofacial Pain.* 2004;172:8-9. [Author: Please verify ref. 6. Could not find on PubMed.]
7. Tasaki MM, Westesson PL. Temporomandibular joint: diagnostic accuracy with sagittal and coronal MR imaging. *Radiology.* 1993;186:723-729.
8. Liu ZJ, Yamagata K, Kuroe K, et al. Morphological and positional assessments of TMJ components and lateral pterygoid muscle in relation to symptoms and occlusion of patients with temporomandibular disorders. *J Oral Rehabil.* 2000;27:860-874.
9. Szentpetery A. Clinical utility of mandibular movement ranges. *J Orofac Pain.* 1993;7:163-168.
10. Ai M, Yamashita S. Tenderness on palpation and occlusal abnormalities in temporomandibular dysfunction. *J Prosthet Dent.* 1992;6:839-845.
11. Okano N, Baba K, Akishige S, et al. The influence of altered occlusal guidance on condylar displacement. *J Oral Rehabil.* 2002; 29:1091-1098.
12. Linde C, Isacson G. Clinical signs in patients with disk displacement versus patients with myogenic craniomandibular disorders. *J Craniomandib Disord.* 1990;4:197-204.
13. Becker I, Tarantola G, Zambrano J, et al. Effect of a prefabricated anterior bite stop on electromyographic activity of masticatory muscles. *J Prosthet Dent.* 1999;82:22-26.
14. Carroll WJ, Woelfel JB, Huffman RW. Simple application of anterior jig or leaf gauge in routine clinical practice. *J Prosthet Dent.* 1988;59:611-617.
15. Neff P. *TMJ, Occlusion and Function.* 8th ed. Georgetown University School of Dentistry, Washington, DC, 1999
16. Dawson PE. *Evaluation, Diagnosis and Treatment of Occlusal Problems.* 2nd ed. St Louis, MO: Mosby Year Book, Inc; 1998.
17. Goldstein L. Use of the Best-Bite anterior discluder for the treatment of migraine headache. *J Funct Orthod.* 2004;21: 34-37.
18. Dawson PE. A classification system for occlusions that relates maximal intercuspation to the position and condition of the temporomandibular joints. *J Prosthet Dent.* 1996;75:60-66.
19. Parker MW. The significance of occlusion in restorative dentistry. *Dent Clin North Am.* 1993;37:341-351.
20. Dawson PE. New definition for relating occlusion to varying conditions of the temporomandibular joint. *J Prosthet Dent.* 1995;74:619-627.
21. Barker DK. Occlusal interferences and temporomandibular dysfunction. *Gen Dent.* 2004;52:56-61.
22. Murakami K, Seamy N, Fujimura K, et al. Correlation between pain and sinusitis in patients with internal derangement of the temporomandibular joint. *J Oral Maxillofac Surg.* 1991;49:1159-1162.

Quiz 2

1. **The differential diagnoses of restricted mandible opening include:**
 - a. trauma from a fractured jaw.
 - b. muscle spasm as a result of occlusal interference.
 - c. closed lock.
 - d. all of the above
2. **The “spray and stretch” technique is the traditional clinical method of:**
 - a. relaxing the muscles.
 - b. centering the jaw joints.
 - c. eliminating muscle spasm.
 - d. capturing an open bite record.
3. **The only method to be certain of the position of the disc is through:**
 - a. palpation via the external auditory meatus.
 - b. temporomandibular joint (TMJ) tomogram.
 - c. magnetic resonance imaging (MRI).
 - d. joint sounds.
4. **In this case, the jaw joints were clearly destabilized by:**
 - a. the shape of the condyle.
 - b. the development of the skull.
 - c. the unbalanced occlusion at maximal intercuspal position of the teeth.
 - d. the muscles.
5. **Pain both in the muscles and the jaw structures:**
 - a. is just over the jaws joints.
 - b. is just in the teeth.
 - c. is just in the facial region.
 - d. can radiate and refer.
6. **With the 8 degree incisal table of the discluder acting as a fulcrum and guide, and the muscles acting as a force:**
 - a. occlusal interferences are prohibited.
 - b. condyles are assisted to seat up into a centered position.
 - c. muscles relax.
 - d. all of the above
7. **In this case, limited opening was in fact the result of:**
 - a. a joint derangement.
 - b. muscles.
 - c. previous surgery.
 - d. anticipated surgery.
8. **The procedure of equilibrating the patient’s teeth directs the vertical forces generated by the jaw muscles:**
 - a. down the long axis of the posterior teeth as far as possible.
 - b. down the short axis of the posterior teeth as far as possible.
 - c. down the long axis of the anterior teeth as far as possible.
 - d. down the short axis of the anterior teeth as far as possible.
9. **Equilibrating the teeth directs the nonaxial forces when the person bites side to side:**
 - a. as far as possible from the fulcrum where the forces are weakest.
 - b. as far as possible from the fulcrum where the forces are greatest.
 - c. as close to the fulcrum as possible.
 - d. directly on the fulcrum.
10. **Displaced joints:**
 - a. always cause pain.
 - b. never cause pain.
 - c. do not always cause restricted movements and pain.
 - d. displace laterally only.

Please see tester form on page xx.

This article provides 1 hour of CE credit from Ascend Media’s Dental Learning Systems, in association with the University of Southern California School of Dentistry and the University of Pennsylvania School of Dental Medicine, representatives of which have reviewed the articles in this issue for acceptance. Record your answers on the enclosed answer sheet or submit them on a separate sheet of paper. You may also phone your answers in to (888) 596-4605 or fax them to (703) 404-1801. Be sure to include your name, address, telephone number, and the last 4 digits of your Social Security number.